

RESEARCH ARTICLE

Microapical surgery management of root resorption in anterior teeth caused by dental trauma: case report

Jiang Wang[†], Yang Yang[†], Yingjie Wang, Yanli Liu, Yongjin Chen and Min Zhang*

State Key Laboratory of Military Stomatology & National Clinical Research Center for Oral Diseases & Shaanxi International Joint Research Center for Oral Diseases, Department of General Dentistry and Emergency, School of Stomatology, Fourth Military Medical University, Xi'an, China

Abstract

Root resorption (RR) is a common complication of traumatic dental injuries (TDIs), which could result in tooth loss and affect life in severe cases. The management of a traumatized tooth with RR remains a challenge for clinicians. In our presented cases, the impacted teeth had a history of trauma and underwent thorough non-surgical endodontic treatment; however, RR still occurred months later and could be observed through a periapical radiograph. Therefore, root canal therapy was performed under a dental microscope with a quick-setting calcium silicate cement to repair the RR site. After a long follow-up, the affected teeth showed almost complete healing of the periradicular tissues without sign of RR. This report demonstrates that external root absorption is typically a consequence of traumatized teeth. However, to date, there is still no effective method for its treatment. Here, we successfully applied microscopical surgery to the traumatized teeth experiencing root absorption and provided them with a new healing opportunity.

Keywords: *root resorption; replacement root resorption; microapical surgery; dental operating microscope; mineral trioxide aggregate (MTA)*

Received: 21 November 2021; Revised: 2 December 2021; Accepted: 4 December 2021; Published: 6 January 2022

Traumatic dental injuries (TDIs) frequently occur in children and adolescents and can exhibit significant sequelae during their lives (1). Its prevalence in permanent dentition varies from studies and countries, with an extensive range from 2.4 to 58.0% (1, 2). As an essential complication of TDI, root resorption (RR) mainly manifests as a loss of dental hard tissue, including cementum and dentine. RR includes external and internal RR, which differ from the location of the absorption (3, 4). External RR is typically a prevalent consequence of severe trauma and is classified into surface RR (SRR; 13.3%), inflammatory RR (IRR; 23.2%), and replacement RR (RRR; 51%) in ascending order of frequency (5, 6).

Since the replantation of avulsed teeth, SRR can occur 1 week later with a low incidence, reversibility, and good prognosis (3, 5, 7, 8). IRR following replantation of avulsed teeth can be found in these cases, showing loss of periodontal ligaments, damage to root tissues and

necrosis, and infection of the dental pulp. Radiologic characteristics can be first observed approximately 2 weeks after the avulsed teeth replantation (8). Standardized root canal therapy can control the occurrence and development of periapical inflammation and slow the speed of IRR but cannot completely prevent the occurrence of absorption. IRR can usually be diagnosed within 2 years because resorption is significantly reduced after trauma. If the avulsed teeth do not receive standardized root canal therapy, the radiologic findings of IRR can be observed clearly within 3 months. RRR usually begins 2 weeks after replantation of the avulsed teeth (9). An imaging examination can confirm the occurrence of such absorption at 4–6 months after trauma. When RRR occurs, the root tissue is replaced by bone tissue gradually and erodes the whole root until it is completely replaced.

The clinical symptoms of RR are often not obvious, and an imaging examination mainly confirms its diagnosis. A

[†]Authors share the equal work.

low density of tissue destruction on root tissue has been observed on the X line. Cone Beam Computed Tomography (CBCT) has more clinical significance for diagnosing RR and can accurately show the location and scope of absorption. In general, conventional root canal treatment cannot effectively prevent the process of RR for traumatized teeth. To date, there is still no effective method for treating tooth root absorption in traumatized teeth. Microscopic apical surgery can remove the diseased root tissue by mechanical cleaning and repair the root with bioceramic material through gingival flap exposure of the root and periapical tissue (10). Therefore, we considered that apical surgery might provide a new treatment opportunity for the root absorption of traumatized teeth, likely controlling periapical inflammation by removing the diseased root tissue to prevent further absorption using bioceramic materials effectively.

The case reports below described the surgical management of maxillary traumatized incisors with RR. The affected incisors had a history of trauma and underwent thorough non-surgical endodontic treatment; however, RR still occurred months later. Therefore, we decided to use microscopical surgery to repair the RR site and preserve the traumatized tooth.

Case report I

A female patient at 21-year-old had no contributory medical history and was brought to manage RR associated with a maxillary incisor in our department. It was recorded that she had a traumatic injury involving her upper front teeth approximately 6 months earlier. She had undergone a standardized sequential treatment of tooth trauma at our hospital. However, she revisited our facility on her doctor's advice, and we observed that the affected teeth exhibited RR through intraoral radiography.

The clinical examination revealed temporary restoration in the crowns of teeth 11, 12, 13, and 21. Cold testing with tetrafluoroethane spray on teeth 11, 12, 13, and 21 did not elicit pain. Percussion on the affected teeth did not produce pain except tooth 21, which had a metallic

sound. In addition, these teeth were not mobile, and the gingival mucosa was normal. The periapical radiographs (Intraoral dental X-ray device, FOCUS, Instrumentarium Dental, Finland) of teeth 11, 12, 13, and 21 showed good root canal filling and no apparent abnormalities in the periapical region except for teeth 11 and 21. The gutta-percha cone was overcharged at approximately 0.5 mm of tooth 11. Approximately 4 mm of root structures were destroyed from the apical of the root, with the root and bone blending into a moth-eaten appearance, and the periodontal ligament image was not continuous from tooth 21 (Fig. 1a). The 2D images demonstrated the RR of tooth 21. Due to unclear and imprecise images, it was difficult to determine the extent of the lesion and its relation to the surrounding bone. Therefore, a preoperative CBCT image was requested. An RRR of approximately 4 mm in the apical region of tooth 21 was shown in the CBCT image (Hires3D, Beijing, China) (Fig. 1b).

We established an RRR diagnosis that affected tooth 21 relays on clinical presentation and radiographic images. The patient received and accepted a treatment plan that included endodontic surgery with a fast-setting calcium silicate cement on the lesion area of tooth 21. The dental operating microscope (DOM) (Global Surgical Co., Saint Louis, MO, USA) was used through all surgical procedures except incision, suturing, and flap elevation. We obtained an informed consent and explained the clinical situation and risks during and after treatment. After the local anesthesia (1.8 mL of 3% mepivacaine chlorohydrate with 1:50,000 epinephrine), the vestibular incision and the submarginal flap elevation exposed the lesion. The destruction of bone and root structure in the apical region was apparent. Then, we located the root and removed the surrounding lesion. Staining confirmed that the apical section was healthy and showed no absorption damage with 1–2% methylene blue by microscopy. Driven by a piezoelectric ultrasonic unit (P5, Satelec, Merignac, France), a 3-mm depth cavity was prepared via a KiS ultrasonic tip (ObturaSpartan, Fenton, MO, USA). After

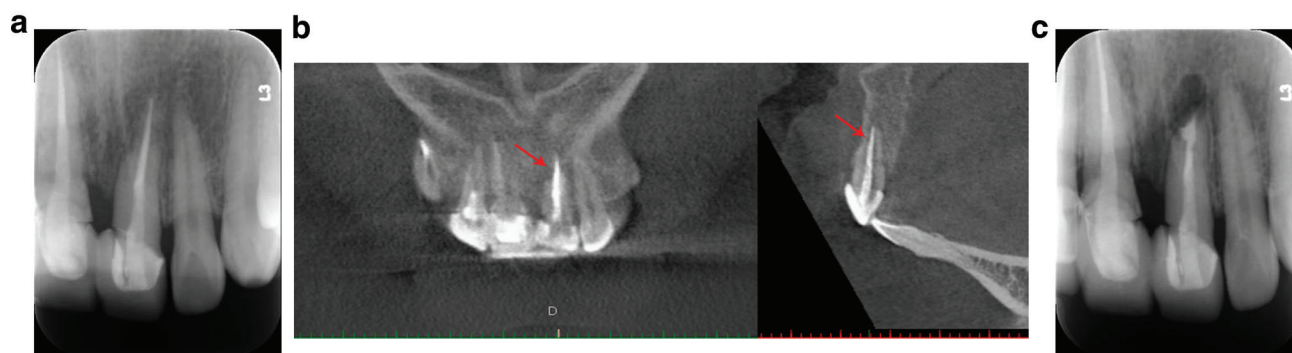


Fig. 1. Diagnostic radiograph showing the RRR lesion of tooth 21 (a), CBCT scan showing an RRR lesion image (b), and post-operative radiograph indicating that the lesion was removed and the root-end cavity was adequately filled (c).

drying, a fast-setting calcium silicate cement (Endocem MTA, Maruchi, Wonju, Korea) was filled into the cavity. Before wound closure, the surgical field was carefully checked and rinsed. Last, the soft tissue flap was repositioned and sutured with single interrupted sutures. The fine suture material (5-0) was the best choice. The periosteal tissue was taken to contact the bone under slight compression with gauze. We performed periapical radiography to ensure the effect of surgery immediately (Fig. 1c). The patient was provided with postoperative care instructions. At 1, 3, 6, 12, and 24-month follow-ups, the patient had no symptoms at all. Radiographic follow-ups at 1st, 2nd, and 3rd year showed that the periradicular tissues were almost completely healed, and there was no sign of RR (Fig. 2a–c). In addition, CBCT at 24 months observed the same outcome (Fig. 3).

Case report 2

A 23-year-old female patient was managed RR associated with a maxillary incisor in our department. The patient

reported that her upper front teeth had RR from an injury occurring approximately 6 months earlier and underwent a standardized sequential tooth trauma treatment in our hospital.

A clinical examination revealed that teeth 11 and 12 had the whole crown and resin fillings, and tooth 21 had a defect in the mesio-incisal angle. Cold testing with tetrafluoroethane spray and percussion on teeth 11, 12, and 21 did not elicit pain. In addition, these teeth were not mobile, and the gingival mucosa was normal. A periapical radiograph showed good root canal filling and no obvious abnormality in the periapical region of tooth 21. A semi-circular root canal lesion was seen near the lower 1/3 of the root of tooth 11 that had no apical lesions. A damaged apex with an extra-filled gutta-percha cone overcharged was shown in a periapical radiograph of tooth 12 under a well-defined radiolucent area (Fig. 4). A CBCT image showed an IRR in the mesio-lower 1/3 of the root canal of tooth 11 and similar resorption in the apical of tooth 12 (Fig. 5). Therefore, an IRR diagnosis affected teeth 11

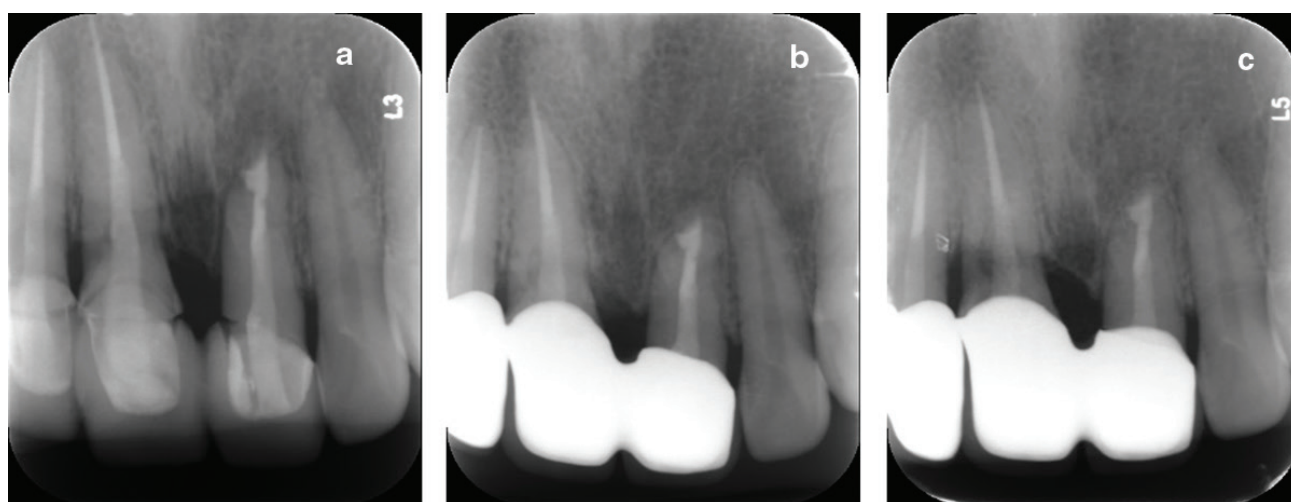


Fig. 2. (a) A 12-month follow-up radiograph showed the healed periapical lesion and no sign of root resorption; (b) a 24-month follow-up radiograph showed no sign of root resorption; (c) a 48-month follow-up radiograph showed no sign of root resorption.

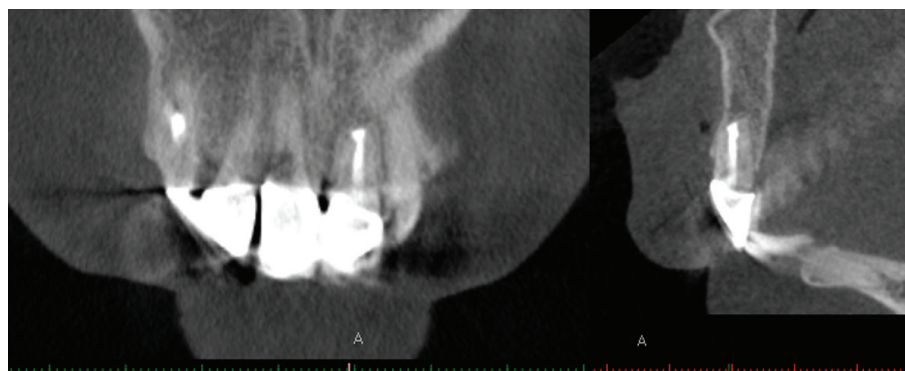


Fig. 3. A 24-month follow-up CBCT scan showed the healed periapical lesion and no sign of root resorption.

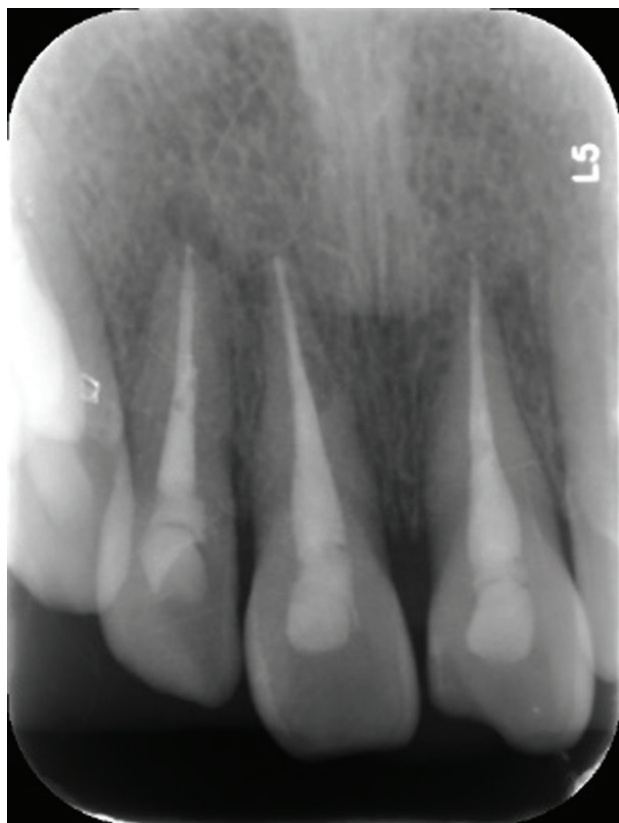

Fig. 4. Diagnostic radiograph showing the IRR lesion of teeth 11 and 12.

and 12 was established. A treatment plan of surgical endodontic management using a DOM (Global Surgical Co., Saint Louis, MO, USA) was presented and accepted by the patient.

After the local anesthesia, the full mucoperiosteal flap was reflected to expose the lesion. The lesion of tooth 11 in the lower 1/3 of the root and approximately 3 mm from the apex was elliptical, with a size of roughly 2 mm × 1 mm. Root failure was determined by methylene blue staining, and the granulated tissue was completely removed using a small excavator spoon and a round burr. After the absorption site was cleared, mineral trioxide aggregate (MTA) was used to repair the damaged root (Fig. 6). After the bony window of tooth 12 was prepared, we located the root apex and removed the surrounding lesion. Driven by a piezoelectric ultrasonic unit, a 3-mm depth cavity was prepared via a KiS ultrasonic tip. After drying, a fast-setting calcium silicate cement was filled into the cavity. Finally, the soft tissue flap was repositioned and sutured using single interrupted sutures. The fine suture material (5-0) was the best choice. We performed periapical radiography to ensure the effect of surgery immediately (Fig. 7) and provided postoperative care instructions for the patient. The radiographic follow-ups at 6 months and 1 year presented the periradicular tissues were almost

ideally healed, and no more root absorption was observed (Fig. 8).

Discussion

RR is a common complication after dental trauma existing in young people. Despite the unclear mechanisms responsible for RR, dental trauma is regarded as the main potential predisposing factor (6). The pulp, root apex, cementum, periodontal ligament, or peripheral bone could be injured individually or combined. The injury reduced the resistance of pulp and periodontal tissues to bacterial invasion associated with the trauma and the resistance of root surface to resorption of bone cement at the injured site (11). So far, unpredictable and ineffective treatments nearly could not heal RR. Calcium hydroxide intracanal dressing is the most widely used RR treatment that can attenuate the progression but does not prevent resorption (12). Furthermore, some studies have indicated that the timing of the pulpectomy impacted the occurrence and severity of the initial RR (13). It also revealed that the risk of RR was significantly increased when pulp extirpation was delayed more than 14 days (14). In our cases, after performing the meticulous non-surgical endodontic treatment, the affected teeth still had RR, possibly because of delaying pulp extirpation when initial RR occurred. Uncontrolled RR will eventually lead to considerable root tissue damage, resulting in tooth loss. Therefore, we considered that apical surgery might provide a new treatment opportunity for root absorption in traumatized teeth.

Apical surgery aims to surgically maintain a tooth with significant root canal damage, which is unsolvable by traditional endodontic (re)treatment (10, 15). Therefore, for several decades, DOM has been strongly recommended to enhance and facilitate endodontic surgery (16–18). Notably, DOM offers a high-magnification surgical field. It provides well-focused illumination, detects additional root canals, isthmus, and root integrity, distinguishes bone from the root, and identifies adjacent critical anatomical structures (10).

According to our treatment experience, the timing of surgical treatment varies depending on the different characteristics of IRR and RRR. For IRR, if the avulsed teeth have been given prestandardized tooth trauma treatment and dental pulp treatment, which means that the necrotic pulp is thoroughly cleaned and the inflammation around the apical period is effectively controlled, the traumatized teeth can be observed continuously for another 3–6 months after exact inflammatory resorption was found (3, 8, 19). At a period of 6–12 months after the trauma, if the progressive IRR was clearly defined, microscopic root canal surgery could be performed. For RRR, early imaging features are not obvious, and only the metallic percussion sound of the avulsed teeth may indicate the occurrence of RRR. This can be confirmed by imaging

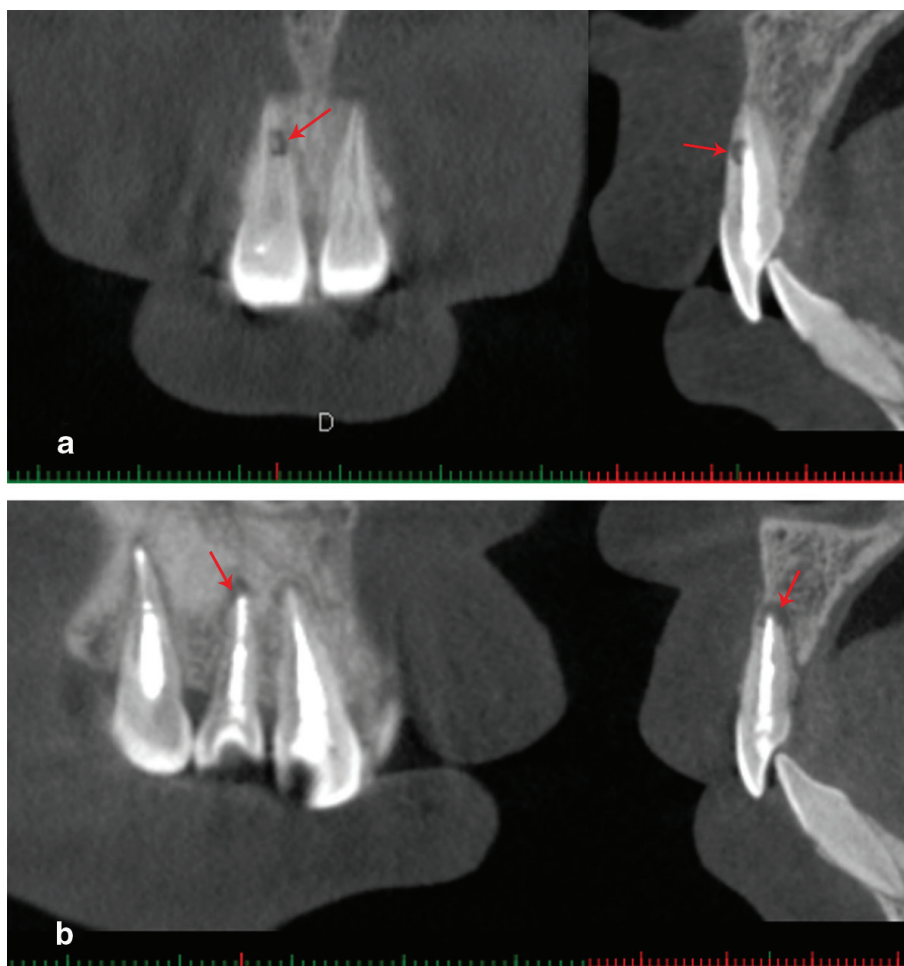


Fig. 5. (a) CBCT scan showed an IRR lesion image in the lower 1/3 of the root of the affected tooth 11; (b) CBCT scan showing an IRR lesion image in the apex of the root of the affected tooth 12.

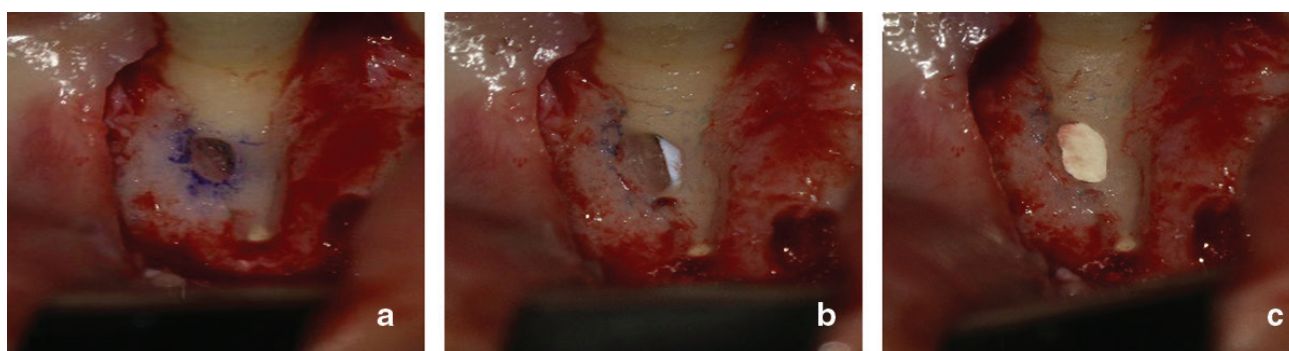


Fig. 6. (a) The lateral lesion of tooth 11 was detected; (b) the lateral lesion was removed and checked; (c) MTA repaired the lateral lesion.

examination at least 4–6 months after trauma. Once RRR occurs, it will gradually spread to the whole root, so when an imaging examination confirms local replacement absorption of the root of the avulsed tooth, it is time to remove the lesion of the root and retain the normal root

that has not been invaded through microsurgery (3, 8, 19, 20). In our cases, the affected teeth had been diagnosed with RR and had been injured for more than 6 months, so we did not continue observation and moved to direct surgical intervention.

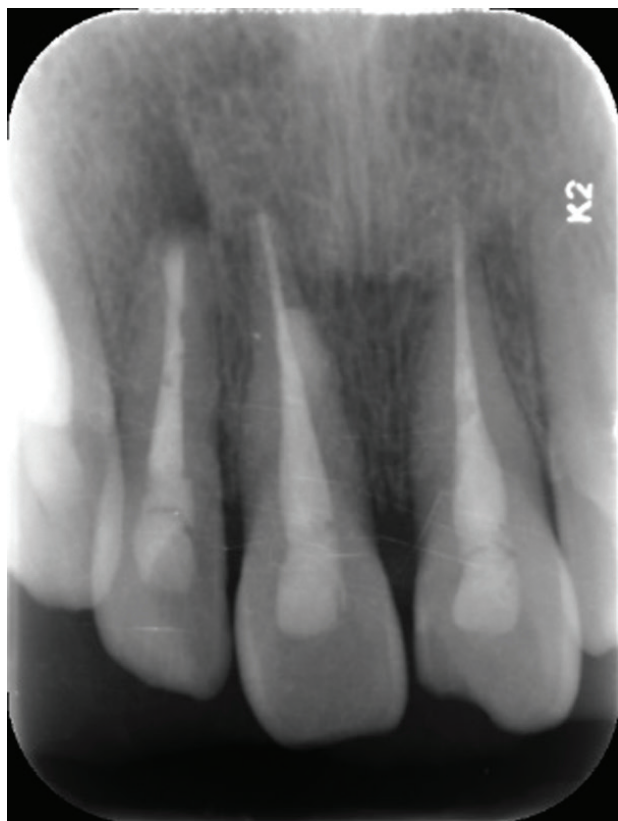

Fig. 7. Postoperative radiograph indicating that the lesion of tooth 11 was filled, the lesion of tooth 12 was removed, and the root-end cavity was adequately filled.

In addition, the *modus operandi* was different for Case 1 and Case 2. For Case 1, RR occurred in the apex of the root, so the *modus operandi* was root amputation. However, in Case 2, the affected tooth (#11) had a lesion in the mesio-middle 1/3 of the root canal, and the *modus operandi* was a local repair. The choice of *modus operandi* mainly depends on the location of the lesion. When the site of RR is located in or near the apical region, conventional root amputation may be considered. On the other hand, local repair may be considered when the RR site is situated at the middle of the root or the neck of the tooth. A previous study recommended that fine details of endodontic surgery could be observed and evaluated via high magnification (18× to 30×) (21). In Case 2, after removing the granulated tissue from the lateral lesion, the distal root surface was carefully examined at high magnification (19×), and healthy root tissue was quickly found. Then, we used MTA, a good root-end filling material composed of various calcium silicate cement with excellent biocompatibility, ideal adherence to the cavity walls, and low solubility (22).

RR caused by trauma has unique characteristics: the patient is typically young, complex, and quickly develops. At present, there are guidelines for the standardized dental trauma treatment developed by the International Association of Dental Trauma, but there is no clear treatment guide for RR caused by dental trauma. To the authors' knowledge, this is the first description of

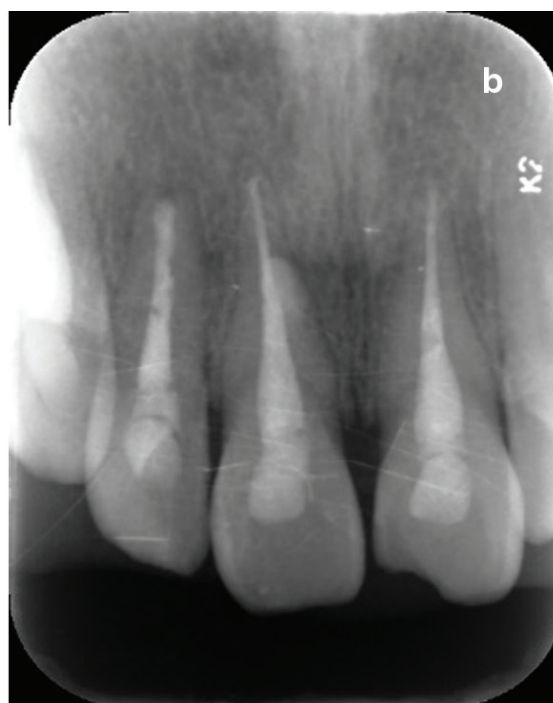
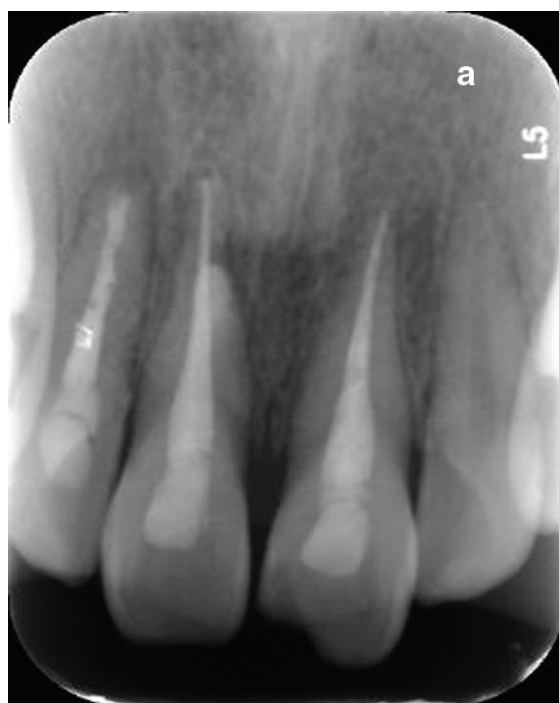
Fig. 8. (a) A 6-month follow-up radiograph showed the healed lesions of teeth 11 and 12; there were no signs of root resorption of the affected teeth 11 and 12; (b) a 12-month follow-up radiograph showed no sign of root resorption of the affected teeth 11 and 12.

applying microscopic apical surgery to treat RR after dental trauma, which we thought is the treatment of last resort to stop the resorption in the early stage and retain the affected tooth. Future research should provide more insight into the long-term effects of traumatized teeth. In addition, the long-term outcome of the surgical effects should be identified via further follow-up in the present cases.

Acknowledgments

This study was supported by the National Clinical Research Center for Oral Diseases Project (LCA202007).

Conflict of interest and funding

The authors confirm that they have no conflict of interest and funding.

References

- Procopio SW, Matos HCA, de Oliveira PLE, de Andrade BAB, Agostini M, Esteves JC, et al. Development of a calcified odontogenic hamartoma following avulsion of a permanent central incisor. *Dent Traumatol* 2020; 36: 298–302. doi: 10.1111/edt.12519
- Bilder L, Margvelashvili V, Sgan-Cohen H, Kalandadze M, Levin L, Ivanishvili R, et al. Traumatic dental injuries among 12- and 15-year-old adolescents in Georgia: results of the pathfinder study. *Dent Traumatol* 2016; 32: 169–73. doi: 10.1111/edt.12236
- Gregorczyk-Maga I, Kaszuba M, Olszewska M, Licholai S, Iwaniec T, Koscielniak D, et al. Biomarkers of inflammatory external root resorption as a result of traumatic dental injury to permanent teeth in children. *Archiv Oral Biol* 2019; 99: 82–91. doi: 10.1016/j.archoralbio.2019.01.003
- Mincik J, Urban D, Timkova S. Clinical management of two root resorption cases in endodontic practice. *Case Rep Dent* 2016; 2016: 9075363. doi: 10.1155/2016/9075363
- Zare Jahromi M, Kalantar Motamedi MR. Effect of calcium hydroxide on inflammatory root resorption and ankylosis in replanted teeth compared with other intracanal materials: a review. *Restor Dent Endod* 2019; 44: e32. doi: 10.5395/rde.2019.44.e32
- Yoshpe M, Einy S, Ruparel N, Lin S, Kaufman AY. Regenerative endodontics: a potential solution for external root resorption (case series). *J Endod* 2020; 46: 192–9. doi: 10.1016/j.joen.2019.10.023
- Saoud TM, Mistry S, Kahler B, Sigurdsson A, Lin LM. Regenerative endodontic procedures for traumatized teeth after horizontal root fracture, avulsion, and perforating root resorption. *J Endod* 2016; 42: 1476–82. doi: 10.1016/j.joen.2016.04.028
- Gunraj MN. Dental root resorption. *Oral Surg Oral Med Oral Pathol Oral Radiol Endod* 1999; 88: 647–53.
- Day PF, Duggal M, Nazzari H. Interventions for treating traumatised permanent front teeth: avulsed (knocked out) and replanted. *Cochrane Database Syst Rev* 2019; 2: CD006542. doi: 10.1002/14651858.CD006542.pub3
- von Arx T. Apical surgery: a review of current techniques and outcome. *Saudi Dent J* 2011; 23: 9–15. doi: 10.1016/j.sdentj.2010.10.004
- Fouad AF. Microbiological aspects of traumatic injuries. *J Endod* 2019; 45: S39–48. doi: 10.1016/j.joen.2019.05.011
- von Arx T. [Mineral trioxide aggregate (MTA) a success story in apical surgery]. *Swiss Dent J* 2016; 126: 573–95.
- Bastos JV, Ilma de Souza Cortes M, Andrade Goulart EM, Colosimo EA, Gomez RS, Dutra WO. Age and timing of pulp extirpation as major factors associated with inflammatory root resorption in replanted permanent teeth. *J Endod* 2014; 40: 366–71. doi: 10.1016/j.joen.2013.10.009
- Hinckfuss SE, Messer LB. An evidence-based assessment of the clinical guidelines for replanted avulsed teeth. Part I: timing of pulp extirpation. *Dent Traumatol* 2009; 25: 32–42. doi: 10.1111/j.1600-9657.2008.00727.x
- Floratos S, Kim S. Modern endodontic microsurgery concepts: a clinical update. *Dent Clin North Am* 2017; 61: 81–91. doi: 10.1016/j.cden.2016.08.007
- Levenson D. Review finds better endodontic surgery outcomes with microscope use. *Evid Based Dent* 2012; 13: 108. doi: 10.1038/sj.ebd.6400892
- Setzer FC, Kohli MR, Shah SB, Karabucak B, Kim S. Outcome of endodontic surgery: a meta-analysis of the literature – part 2: comparison of endodontic microsurgical techniques with and without the use of higher magnification. *J Endod* 2012; 38: 1–10. doi: 10.1016/j.joen.2011.09.021
- Kim HJ, Yu MK, Lee KW, Min KS. Surgical management of an accessory canal in a maxillary premolar: a case report. *Restor Dent Endod* 2019; 44: e30. doi: 10.5395/rde.2019.44.e30
- Aidos H, Diogo P, Santos JM. Root resorption classifications: a narrative review and a clinical aid proposal for routine assessment. *Eur Endod J* 2018; 3: 134–45. doi: 10.14744/eej.2018.33043
- Carnio J, Geraldini S, White Jr C. Mineral trioxide aggregate combined with flap surgery for treatment of external root resorption. A long-term clinical case report. *Clin Adv Periodontics* 2015; 5: 254–9. doi: 10.1902/cap.2014.140023
- Kumar R, Khambete N. Surgical operating microscopes in endodontics: enlarged vision and possibility. *Int J Stomatol Res* 2013; 2: 11–15.
- Tsai CL, Ke MC, Chen YH, Kuo HK, Yu HJ, Chen CT, et al. Mineral trioxide aggregate affects cell viability and induces apoptosis of stem cells from human exfoliated deciduous teeth. *BMC Pharmacol Toxicol* 2018; 19: 21. doi: 10.1186/s40360-018-0214-5

*Min Zhang

State Key Laboratory of Military Stomatology & National Clinical Research Center for Oral Diseases & Shaanxi International Joint Research Center for Oral Diseases
Department of General Dentistry and Emergency
School of Stomatology
Fourth Military Medical University
No. 145 West Changle Road
710032 Xi'an
China
Email: cherryzhangmin@126.com